

## A METHOD FOR RE-ENTRANT CANNULATION IN SHEEP

M. IVAN<sup>1</sup> and D.W. JOHNSTON<sup>2</sup>

<sup>1</sup>Animal Research Institute, Agriculture Canada, Ottawa, Ont., Canada, K1A 0C6

<sup>2</sup>Electrical Engineering Division, N.R.C., Ottawa, Ont., Canada, K1A 0R8

A re-entrant cannulation system was developed for the small intestine of sheep in order to overcome problems with post-surgical recovery of sheep, blockage and leakage of digesta, and maintenance of cannulated sheep for an extended period of time. A cannula was moulded in one piece from PVC plastisol. The cannula consisted of a curved intestinal tube joined to a stem with an external elliptic ring on its distal end and a ringed flange which encircled the stem above the intestinal tube. A circular valve with two curved channels was made of perspex to fit into the interior of the cannula which made it interchangeable into either a

« maintenance » or « collection » position (fig. 1). The cannula was inserted into the proximal duodenum or terminal ileum of sixteen sheep, through a 5 cm incision on the antimesenteric side of the intestine. The insertion was achieved by bending the cannula with forceps and releasing it inside the intestine; a Dacron straight arterial graft was used for attachment of the intestine to the cannula (fig. 2). The intestine grew into the graft and thus remained permanently attached to the cannula. The sheep recovered rapidly; the majority of cannulated sheep were eating a regular diet the day after surgery. This was attributed to the fact that

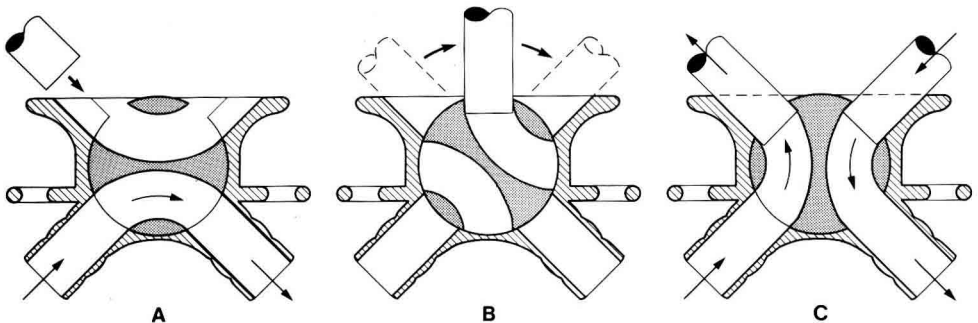


Fig. 1.— View of the function of cannula during the maintenance period (A), interchange (B) and collection period (C). The arrows indicate flow of digesta.

re-entrant cannulation of this type did not require an intestinal transection and a mesenteric incision under the transection, in contrast to other methods. Therefore, very little damage was done to the blood and ner-

vous systems. Some sheep have now been maintained for over one year without apparent blockage or leakage of digesta. All sheep were fed corn silage diet and several collections of digesta have been made.

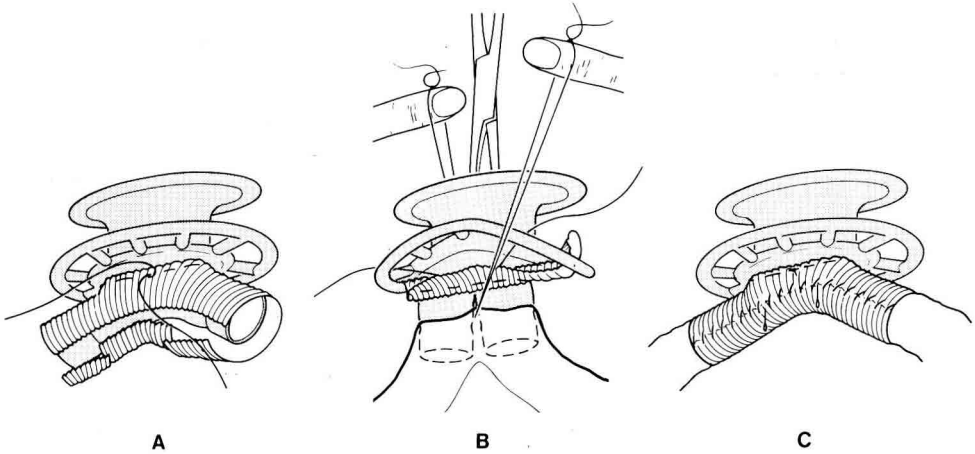


Fig. 2.— Cannula with Dacron arterial graft before (A), during (B) and after (C) the insertion into the small intestine.